

Fixation of Metacarpal and Phalangeal Fractures Using Tension Band Wiring Technique: Prospective Study

Ahmed.S.Ahmed, Islam.A.Tabl and Samir.M.Monieb

Orthopedic surgery Dept., Faculty of Medicine, Banha University

E-mail: midoaid19@gmail.com

Abstract

Background: Metacarpal Fractures of the and phalanges are typical hand injuries that often need for surgical intervention. Kirschner wires (K-wires) and the tension band wiring technique are often employed for open reduction and internal fixing. However, its use in clinical practise must be informed by a careful assessment of its benefits, drawbacks, and consequences. The purpose of this research was to compare the outcomes of open reduction and internal fixation (ORIF) using Kirschner wires (K-wires) and a tension band wiring approach for the treatment of phalangeal and metacarpal fractures. Methods: Twenty patients at Benha University Hospitals had metacarpal or phalangeal fractures in this prospective investigation. K-wire tension band wiring was used for open reduction and internal fixing. Patient characteristics, fracture characteristics, injury causes, time to surgery, and co-morbidities were all evaluated clinically. In radiological evaluations, the conventional perspectives were used. Six months of postoperative monitoring included checks on range of motion, grip strength, and alignment. The Belsky scale was employed to measure functional results, and both patient happiness and complications were recorded. Results: There was a statistically significant increase in mean TAM from 6 weeks post-op to 3 months post-op, as measured by TAM ($p=0.008$). Six months after surgery, TAM was significantly higher than it had been six weeks after surgery ($p0.001$). There were three patients who scored well (17.6 percent), eight patients who scored favourably (47.1 percent), and six patients who scored poorly (35.3 percent) after six weeks. The Belsky score was significantly higher three months after surgery compared to six weeks after surgery ($p=0.023$). Twelve patients (70.6%), or slightly more than half, had an excellent score at 6 months, while four patients (23.5%) had a good score, and only one patient (5.9%), or slightly less than half, had a bad score with substantial improvement from 6 weeks post-operation ($p=0.04$). Conclusions: When treating metacarpal and phalangeal fractures, open reduction and internal fixation with Kirschner wires (K-wires) utilising the tension band wiring approach has been shown to be a safe and successful treatment option.

Key words : Metacarpal, Phalangeal, Open reduction, Kirschner wires and Internal fixation.

1 Opening Remarks

The most prevalent types of upper limb fractures result in a permanent loss of upper limb dexterity, especially metacarpal and phalangeal fractures. Longitudinal and transverse arches may be seen in both the metacarpal and phalangeal bones [1]. The palmer surface of these bones is concave and they are linked at the proximal and distal ends by ligaments. Metacarpal shaft fractures are most often brought on by direct blows, axial stress, and torsional loading [2, 3].

When it comes to hand fractures, metacarpal breaks are the most prevalent kind. Metacarpal fractures occur 8.4 times per 10,000 people every year. These may manifest as a single broken bone, numerous broken bones in the metacarpus, or multiple broken bones in different extremities. Between 18 and 44 percent of all hand fractures [3] occur in the metacarpals.

Because of its proximity to the skin and their function as a means of protection against injury, metacarpals are often broken. Men make up up to 85% of patients suffering from metacarpal and phalangeal fractures. The fifth metacarpal is the most often broken

among the metacarpals. Fractures of the metacarpal may be categorised as either head, neck, shaft, or base fractures. Transverse, short oblique, long oblique, and comminuted are the several types of fracture patterns [4].

Early mobility by open reduction and internal fixation is essential for treating displacement and any associated neurological and vascular damage to restore as much normal function and architecture as possible. Joint stiffness, swelling, and adhesion to normally free gliding components are all reduced by early mobilisation. The ultimate aim in every fracture is to return to normal mobility, however there is still some controversy about the best method for stabilising the fracture [5].

Even within the same medical facility, two surgeons may have vastly different approaches to fracture therapy. Conservative management, tension band wiring using Kirschner's wire (K-wires), plates, and screws are all possible forms of therapy [6]. Nonetheless, there are substantial characteristics connected with each approach that should be taken into account in cases

when one approach is obviously superior to the other [7].

Other than proper reduction and fixation, several aspects impact recovery of adequate mobility, including the manipulation of tissues, the preservation of glide planes for tendons, the avoidance of infection, and early and suitable rehabilitation. Deformity from insufficient therapy, stiffness from overtreatment, and deformity and stiffness from inadequate treatment are all potential complications of metacarpal and phalangeal fractures [8].

The best stabilisation and fixation approach would prevent further movement of the hand, be inexpensive, and restore normal rotation, length, alignment, and function. Miniplates and Kirschner wires (K-wires) are two options for internal fixation. When compared to the miniplate method, using K-wires provides a number of benefits, including superior material, little dissection, technical simplicity, and availability [9].

Tension band method for definitive reduction and fixation using a (1.2-1.4) mm K-wire passing proximal to distal and perpendicular to the fracture. As an internal splint, two k-wires were employed to counteract the effects of rotation and angular displacement [10].

The purpose of this research was to examine the outcomes of open reduction and internal fixation (ORIF) using Kirschner wires (K-wires) utilising a tension band wiring approach for treating phalangeal and metacarpal fractures.

2. Techniques

Patients:

The purpose of this prospective research was to examine the outcomes of open reduction and internal fixation (ORIF) with Kirschner wires (K-wires) utilising a tension band wiring approach for the treatment of phalangeal and metacarpal fractures. Twelve patients were included in the research because they were candidates for open reduction and internal fixation with Kirschner wires (K-wires) utilising the tension band wiring method for metacarpal and phalangeal fractures. The study lasted from January 2022 to January 2023 and took place at Benha University Hospital.

Fractures of the metacarpal or phalangeal shafts, either alone or in multiples, were included. Metacarpal shortening (>5 mm), angulation of the fracture > 30 degrees, rotational deformity > 10 degrees, and irreducible or unstable fractures all need surgical intervention.

Non-union of metacarpal or phalangeal fractures, intra-articular metacarpal fracture, and patients with previous fractures were all disqualified.

The following were part of the extensive assessment process for each patient:

A. Demographic Information We collected information on our patients' ages, sexes, occupations, dominant hands, health histories, and levels of functioning before their injuries. This also included the patient's medical history, including the cause of their current condition, the side of their body that was injured, how long it had been since the accident occurred, and their symptoms (such as pain, edoema, and restricted motion in their afflicted finger). Medication and allergy records were also kept, along with a patient's medical and surgical histories.

B. General Examination: A comprehensive general examination was performed to evaluate neurovascular function, check skin abrasions or wounds, determine the presence or absence of tendon injuries, and assess discomfort over the affected metacarpal or phalanx for swelling or deformity.

Anteroposterior, lateral, and oblique plain radiography images of the afflicted finger were taken to evaluate the fracture's position, pattern, direction of displacement, angulation, rotation, pin placement, and the presence of any related fractures.

D. Invasive Surgery: Patients received either general, regional, or local anaesthetic, depending on the kind of surgical procedure being performed. They lay supine with their arm supported on a radiolucent table at a right angle to their torso. The use of intraoperative imaging (C-arm) for guiding was necessary. K-wires of 1.2-1.4 mm in diameter were placed perpendicular to the fracture and passed from proximal to distal as part of an open reduction and internal fixation procedure employing a tension band approach to stabilise the fracture. The treatment method included extensive post-operative follow-up and rehabilitation.

Technique of care:

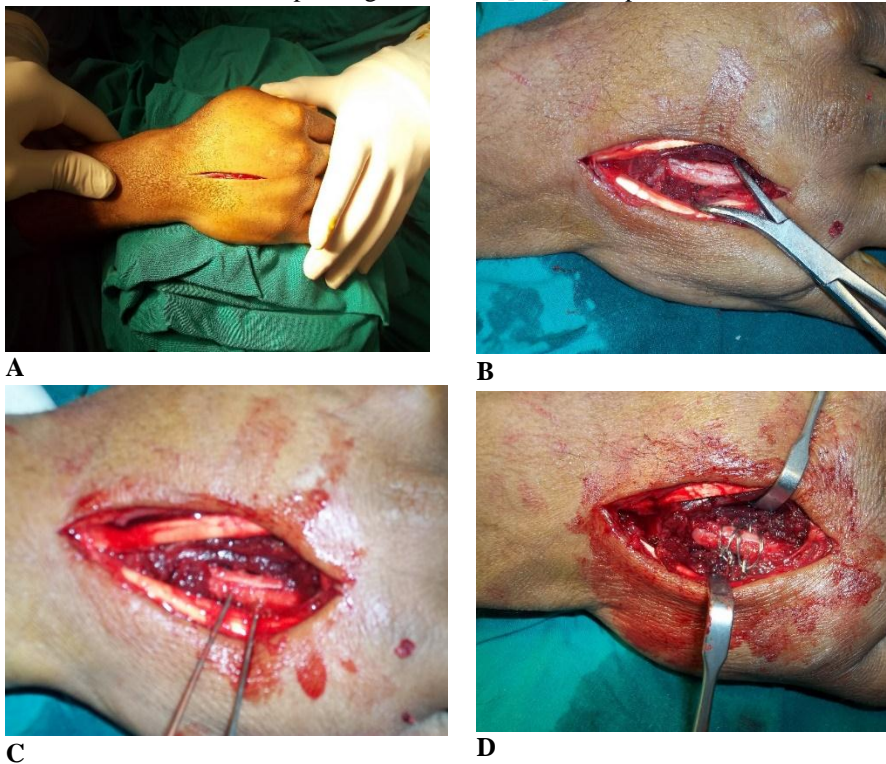
All patients received a temporary splint for the injured area, with an ulnar gutter slab for ring or little finger fractures, a radial gutter slab for index or middle finger fractures, a thumb spicca for fractures of the thumb, and a volar slap for fractures of the metacarpal. Up to the time of surgery, patients were provided limb elevation while also receiving analgesics and anti-oedematous treatment.

The fracture was exposed using either general or local intravenous anaesthetic and tourniquet control during the operation.

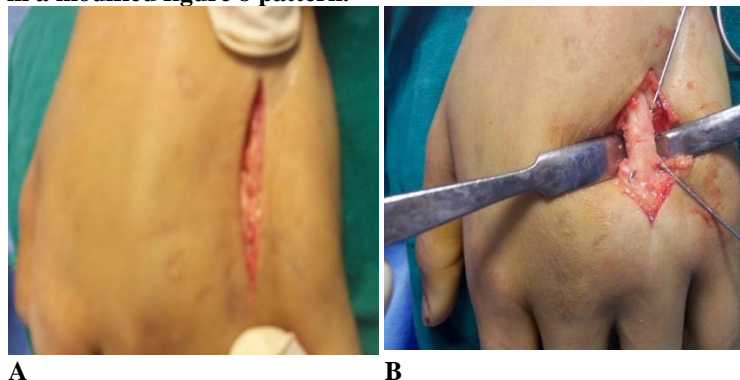
Different surgical techniques were used for different metacarpal fractures. Dorsolateral incisions were used for fractures of the first metacarpal and the proximal phalanx of the thumb, dorsoradial and dorsoulnar longitudinal incisions with curves for fractures of the second and fifth metacarpals, and longitudinal incisions for fractures of the third and fourth metacarpals, including cases of internal fixation when multiple bones were involved, extending distally. Fractures of the proximal and middle phalanx were treated using dorsal lateral incisions. Diagram 1

The fracture is reduced and maintained in place with a tension band before Kirschner wires (0.035 inches for metacarpal fractures and 0.028 inches for phalangeal

fractures) are placed. Kirschner wires are positioned perpendicular to the fracture plane for long oblique or spiral fractures and crossed for transverse or short oblique fractures. The length of the wires sticking out of the cortex on both sides is reduced to around 2 millimetres. The wires should be positioned such that they do not get in the way of the tendons as they glide. The K-wire ends are wrapped with the 26 or 28 gauge monofilament stainless steel wire and then securely twisted. It is possible to create many K-wire/stainless steel wire structures if the fracture is comminuted. Cortical deficiencies on the side of the tension wire should be repaired with cancellous bone grafting first [11]. Example 2



Tension band wiring is shown in Figure 1 for long oblique spiral metacarpal fractures. a cut in the skin. (a) Fracture exposure and reduction using miniature holding forceps. (C) Kirshner wires oriented such that they run parallel to one another and perpendicular to the fracture surface. (d) Kirschner wires with 1–2 mm of cortex removed on each side and a brief twist of the circulage wire near the bones, with a monofilament stainless steel wire wrapped around the protruding ends in a modified figure 8 pattern.



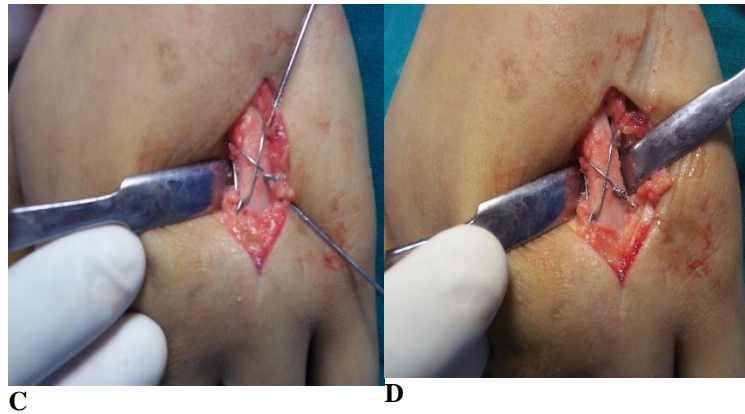


Fig. (2) Technique of tension band wiring in transverse, short oblique fractures. (a) Exposure of the fracture, (b) fracture reduction. (c) Crossed kirschner wires were used. (d) Monofilament stainless steel wire incorporated about the protruding ends of the kirschner wires in a modified figure-of-eight design.

The Identification and protection of superficial nerves and veins. The paratenon was retracted together with the extensor tendons. Over the break, a longitudinal incision was made in the periosteum, leaving as much as possible and protecting the muscle insertions between the bones.

Broken phalanges, type B: A long, curved dorsolateral incision was made to access the proximal and middle phalanx (figure 41.c). It went past the articulations close by. In order to expose the proximal phalanx, a midline longitudinal incision was made through the extensor expansion of the finger. The skin and subcutaneous tissue were then reflected as a flap, protecting the dorsal venous network and the paratenon. Both the proximal and middle phalanges' dorsal bases, where the extensor tendon inserts, were unharmed. The lateral bands were mirrored centrally for fractures of the middle phalanx. In the vicinity of the break, the periosteum was pushed up and kept in tact.

After the internal fixation was finished, we manually applied angular and rotational stresses across the fracture site to determine the fixation's stability. Fingernail curvature and finger orientation were evaluated to ensure proper rotation and angulation.

Sutures were used to secure the periosteum over the implant. Running suture with 5/0 prolene suture was used to seal the periosteum and extensor tendon in the phalanges independently of one another. After carefully releasing the tourniquet and applying compression, hemostasis was achieved. When the fracture was complicated by soft tissue damage and internal fixation was doubtful, the wrist should be immobilised in a modest extension, or volar slap. Once the surgical splint was taken off, full use of the hand was recommended. Patients were instructed to move their hands and fingers as soon as

possible after surgery, provided they could do so pain-free. Sutures were removed, wounds examined, and physical movement was recommended after two weeks. Clinical and radiographic union of the fracture required a monthly follow-up assessment. A modified version of the "Belsky and Eaton" scoring system was used to evaluate the patients.

Evaluation of Outcomes:

Using a goniometer, we measured the active range of motion in each joint of the afflicted finger to calculate the total active motion (T.A.M). The total active range of motion (TAM) was determined by adding the active flexion angles at each finger joint (M.C.P + P.I.P + D.I.P) and subtracting the active extension deficiencies at each joint. T.A.M., flexion range of metacarpophalangeal (M.C.P.) joints, proximal interphalangeal (P.I.P.) joints, and distal interphalangeal (D.I.P.) joints, as well as the presence or absence of deformity and pain, were used in accordance with the "Belsky and Eaton" scoring system to evaluate the success of hand fracture management. T.A.M. and I.P. thumb flexion were added to the system to improve it [1].

Angulation, rotational malalignment, and shortening were all taken into account when determining the severity of a deformity. Using anteroposterior and lateral radiographs, we determined that an angulation of 10 degrees or less was moderate and within an acceptable range, whereas an angulation of 10 degrees or more was considered severe and considerably impaired finger mobility. Clinical evaluations of malrotation included observing the fingernails from various angles and the finger's activity when bent. Finger joint mobility was altered owing to alterations in tendon activity when the degree of malrotation exceeded 5 degrees. When the shortening was larger than 3 mm, it started to affect the range of motion in the finger joints. Strong grip was classified

as > 250 mmHg, average grip was 150-250 mmHg, and weak grip was 150 mmHg; tenderness, discomfort, delay to return to work, and hand grip strength were all subjectively evaluated using a sphygmomanometer cuff held by the afflicted hand.

Statistical analysis: The Statistical Package for the Social Sciences was used for the statistical analysis (IBM Corp. Released 2017, IBM SPSS Statistics for Windows, Version 25.0, Armonk, NY: IBM Corp.). The obtained data was cleaned, coded, and tabulated per parameter type. The Shapiro-Wilk test was used to check for a normal distribution of the data. Means and standard deviations (SD) were computed for numerical data, while frequency and percentage distributions were determined for non-numerical variables as part of the descriptive statistics process. To compare means between two groups, the

Student T Test was used, while the Chi-Square test was used to analyse the associations between two qualitative variables. A p-value of 0.05 at a 95% confidence range was used to establish significance.

3 Outcomes

Twenty people who had broken metacarpals or phalanges participated in the present investigation. In average, they were 35.65 years old (+/-7.98). Patients' ages ranged from 25 to 79, with 25% being under 30, 40% being between 31 and 40, and 35% being over 40. The patients were evenly split between males and females (85% males, 15% females). Males also fared better than females, statistically ($p=0.002$). Ten percent of the patients had hypertension, five percent had diabetes, and the other eighty-five percent had no comorbidities. Table 1

Table(1) Patient characteristics based on the study population

Variable		Total patients n=20	test	p
Age (years)	M ± SD	35.65 ± 7.98	-	-
Age groups, n (%)	<30 years	5 (25%)	$X^2=0.700$	0.705
	31.00 - 40.00 years	8 (40%)		
Gender, n (%)	>40 years	7 (35%)	$X^2=9.800$	0.002*
	Female	3 (15%)		
Comorbidities, n (%)	Male	17 (85%)	$X^2=2.410$	<0.001*
	Hypertension	2 (10%)		
	Diabetes	1 (5%)		
	No comorbidities	17 (85%)		

Chi-squared test (X^2); *P 0.05 considered significant.

Sixty percent of patients were classified as manual labourers, twenty percent as office employees, ten percent as students, and ten percent as housewives. Patients were more likely to suffer injuries to their dominant hand (55%) than their non-dominant hand (45%). The mode of injury in half of the patients was direct impact, whereas in the other half it was indirect. In a statistical breakdown, 18 of the 28 fractures (or 64%) occurred in the metacarpal bones, whereas 10 (or 35%) occurred in the phalangeal bones.

Transverse and spiral fractures each made about 25 percent of the total fractures in the afflicted bones when analysed by fracture pattern. Fractures to the long and short obliques each make about 18% of the total. Minimally comminuted fractures make up just 14% of all fractures but are the least prevalent kind.

Table (2) The typical pattern of bone fractures

Variable	Total fractures n=28	
Pattern of fracture	Minimally Comminuted	4 (14%)
	Long oblique	5 (18%)
	Short oblique	5 (18%)
	Transverse	7 (25%)
	Spiral	7 (25%)

The average number of days preceding an operation was 4.2 (standard deviation: 2.7) days. Furthermore, 18 of the 20 patients (90%) had surgery within a week of their injury, whereas the other 2 patients (10%) had surgery more than a week later. Nineteen of the twenty participants in the study were given general anaesthetic, while the other two got just local intravenous anaesthetic.

The mean total active motion (TAM) increased significantly from 6 weeks to 3 months following surgery (p=0.008). Six months after surgery, TAM was significantly higher than it had been six weeks after surgery (p0.001). Total Physical Activity During Multiple Time Points

Variable		At 6 weeks	At 3 months	At 6 months
TAM	M ± SD	193 ± 19.1	207.2 ± 17	214.6 ± 14
Pairwise comparison			t= 2.952, p= 0.008*	t= 5.994, p= <0.001*

Student's t=Test; Asterisk*: P.05

There were three patients who scored well (17.6 percent), eight patients who scored favourably (47.1 percent), and six patients who scored poorly (35.3 percent) after six weeks. The Belsky score was significantly higher three months after surgery compared to six weeks after surgery (p=0.023). Twelve patients (70.6%), or slightly more than half, had an excellent score at 6 months, while four patients (23.5%) had a good score, and only one patient (5.9%), or slightly less than half, had a bad score with substantial improvement from 6 weeks post-operation (p=0.04). 3rd Figure

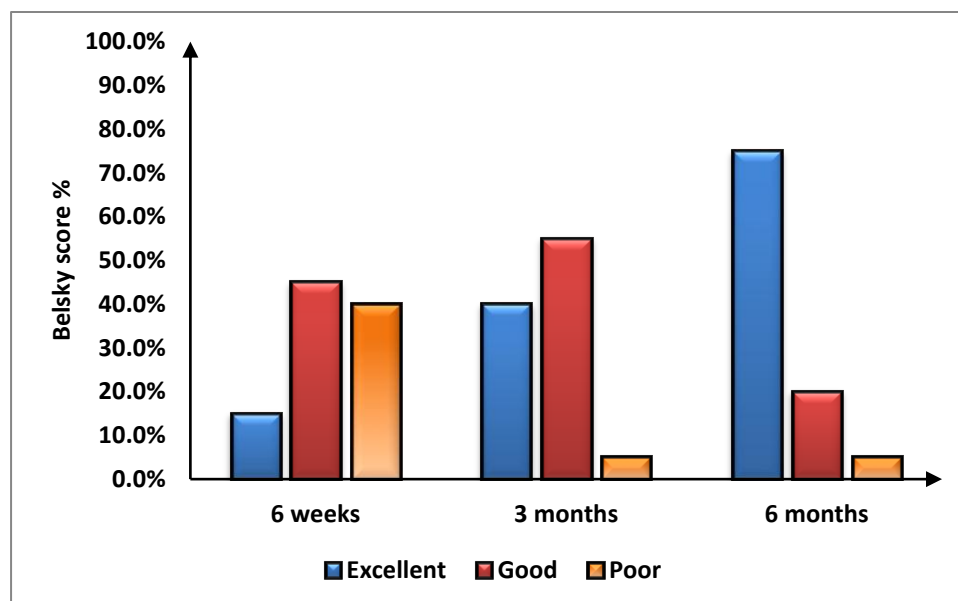


Fig. (3) Belsky rating at various times after the first assessment.

No one who completed the follow-up period reported any discomfort while doing their regular duties. Out of a total of 20 evaluated individuals, 19 patients (95%) did not have any deformity at the conclusion of the follow up period. One patient, or 5%, exhibited a little dorsal angulation of 10 degrees.

Statistically significantly more improvement in mean hand grip was shown at 3 months post-operation compared to 6 weeks post-operation (p0.001). Six months after surgery, there was a statistically significant improvement in hand grip compared to six weeks after surgery (p0.001). A comparison of hand grip strength with time is shown in Table 4.

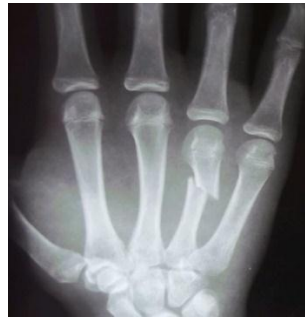Variable		At 6 weeks	At 3 months	At 6 months
Hand grip (mmHg)	M ± SD	162.8 ± 38.3	201.3 ± 34.4	225.2 ± 42
	Strong	0 (0%)	1 (5%)	11 (55%)
Hand grip degree	Average	7 (35%)	17 (85%)	8 (40%)
	Weak	13 (65%)	2 (10%)	1 (5%)
Pairwise comparison			t=5.181 P<0.001*	t=6.914 P<0.001*

T = Student's t Test; * p 0.05

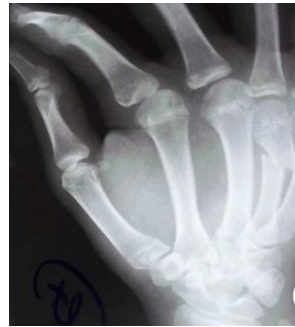Radiological follow-up revealed that 17/25 patients (86%, mean SD, 8.7 0.8 weeks) had radiological union in under 10 weeks. After 10 weeks, radiological union was established in 3 patients (15 percent), with a mean standard deviation of 11.3.0.6 weeks. Eighteen patients (80%) out of the total number of cases analysed went back to work in less than seven weeks, whereas four patients (20%) went back to work after more than seven weeks. Nineteen patients (or 95% of the total number of cases) reported being happy with the results of their operation, whereas just one patient (or 5%) reported being dissatisfied.

4. Cases:

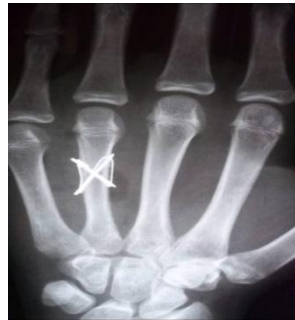Case 1:



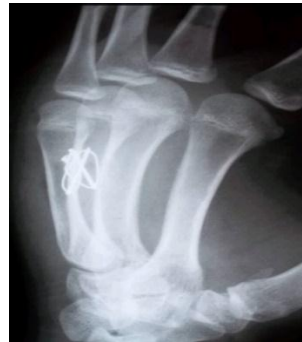A



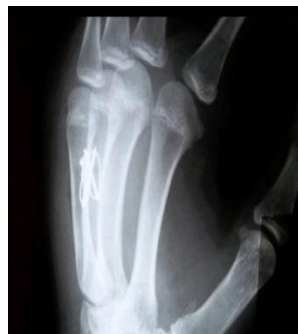B



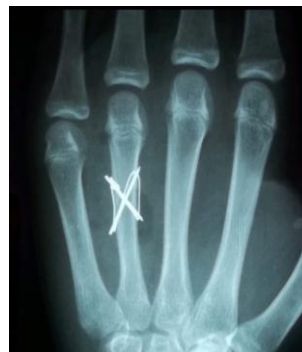C



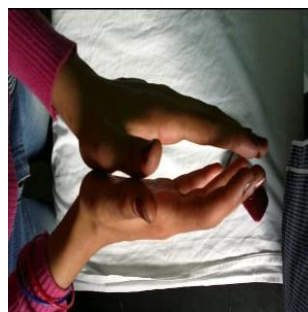
D



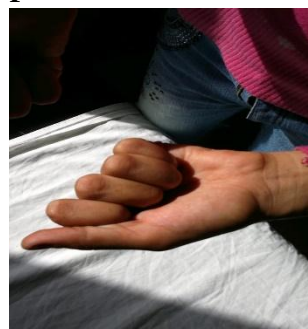E




F



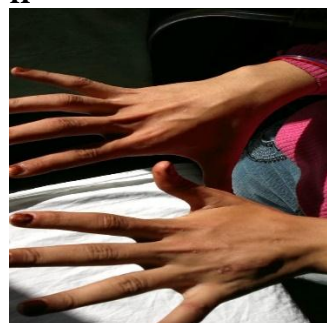
G



H



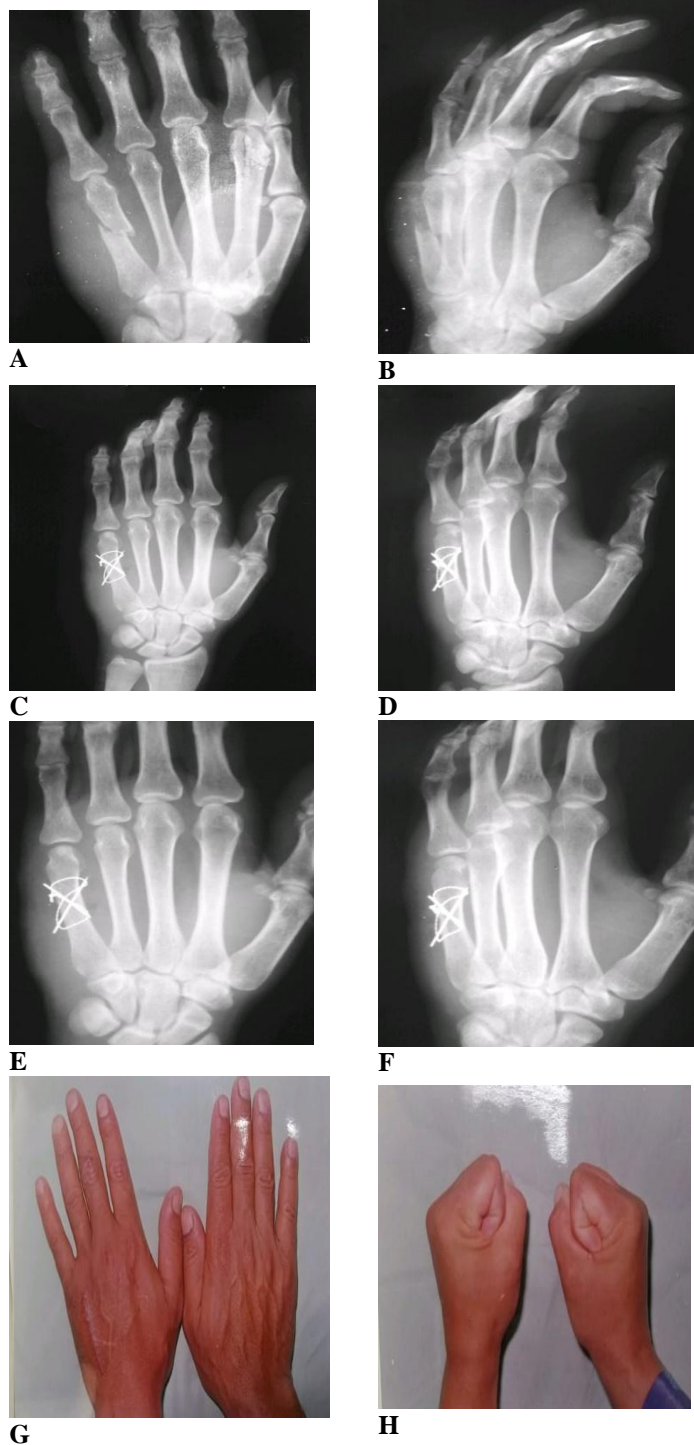
I



J

Fig. (4) A 20-year-old female student who fell and fractured the fourth metacarpal of her nondominant left hand. Cases with very impressive outcomes include: X-rays taken before surgery (A, B), x-rays taken just after surgery (C, D), End-follow-up radiographs (E, F) Mobility of the left ring finger (G, H, I, J) With no aches or disfigurement, T.A.M. 270, P.I.P. 100, and P.I.P. 100 flexion.

Case 2:



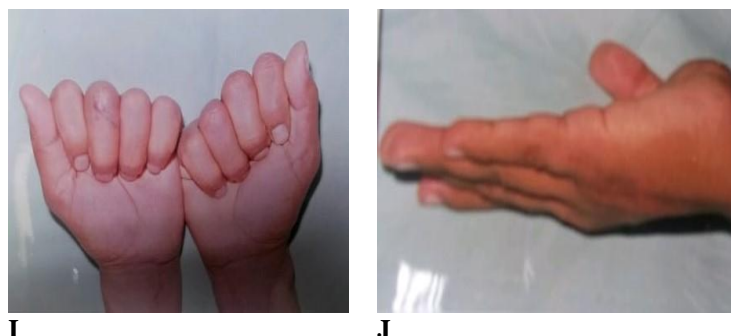


Fig. (5) shows a 22-year-old male student who fell and fractured the fifth metacarpal of his nondominant left hand in a short oblique fashion. Cases where the outcome was positive include: X-rays taken before surgery (A, B), right after surgery (C, D), at the end of follow-up (E, F), with full range of motion and no discomfort or deformity in the left little figure (G, H, I, J) P.I.P. flexion (in degrees): 100 T.A.M.

5. Discourse

Stable fixation, anatomical reduction, and little soft tissue disturbance are some of the benefits of tension band wiring with K-wires, a common surgical procedure for stabilising metacarpal and phalangeal fractures. This strategy encourages early mobility, facilitates fracture healing, and reduces the likelihood of deformity. However, vigilance and monitoring during its application are required due to the possibility of consequences such as pain, K-wire migration or fracture, and, in very rare cases, wire cutting through the bone [2, 3].

Al Shahat et al. conducted a comparative clinical research reviewing the indications and long-term outcomes of each procedure, which mirrors the demographic parameters in the present paper. Twenty patients with hand fractures were treated with percutaneous K wire fixation (group A), ten patients with open reduction and internal fixation with interosseous wiring (group B), and ten patients with open reduction and internal fixation with miniplate and screws (group C) (group C). Patients' ages spanned 15-50, and the great majority were men [4].

Alhumaid et al. also looked at the epidemiology of hand fractures, analysing factors such the most often broken bones, causes, therapies, outcomes, and comorbidities. Patients with traumatic metacarpal or phalangeal fractures were included in the research. They were all treated at King Saud Medical City in Riyadh, Saudi Arabia. With regards to patient information, we have data on 82 people (90% male, average age 27.613.4) [5].

Our findings corroborate those of other research [6, 7] which found that men were more likely to sustain hand fractures. This study's findings of a higher male-to-female ratio for hand fractures ($p=0.002$) provide credence to the hypothesis that men

are disproportionately affected by this kind of injury.

Sixty percent of the patients in the research were classified as heavy manual labourers based on their profession distribution. This result agrees with earlier research showing that people with physically demanding jobs are more likely to break their hands [8, 9]. Twenty percent of patients were office employees, with students and housewives each making up 10 percent of the sample.

Five-and-a-half percent of patients were injured on their dominant side, while nearly half (45 percent) were injured on their non-dominant side. A research by Alhumaid et al. [5] found a similar pattern of hand fractures, with a slightly greater frequency of fractures on the dominant side, consistent with this distribution. Increased exposure to possible traumatic events during tasks conducted with the dominant hand may explain why fractures are more common on the dominant side.

Half of the patients in the research received direct trauma, while the other half had indirect trauma as a result of the trauma they encountered. Fractures in the hand may be classified as either direct (from an impact or crushing) or indirect (from a twisting or bending force) trauma. Previous research has revealed an approximately even split between direct and indirect mechanisms of stress [10, 11], which is consistent with our pattern.

The research found that metacarpal fractures were more common than phalangeal fractures, based on the location of the broken bones. The metacarpal bones accounted for 18 of the 28 fractures (or 64.3%), whereas the phalanges were responsible for 10 (or 35.7%). Metacarpal fractures, especially in the index and middle fingers, have been shown to be more common than previously thought [5].

Phalangeal fractures were found to be somewhat more common than metacarpal fractures (53.5% vs. 46.5%; see also Alhumaid et al., 2015) [5].

The research indicated that transverse and spiral fractures were the most prevalent types of bone fractures, each accounting for 25% of all fractures. These types of breaks often occur as a result of a heavy blow to the hand or a crushing injury [12]. The second most prevalent kind of fracture was either a long or short oblique fracture (18% of all fractures). Bending or twisting forces on the hand often cause these fracture patterns [13]. Minimally comminuted fractures made up just 14% of all fractures, making them the rarest kind. High-energy trauma is often linked with minimally comminuted fractures, which include little fragmentation at the fracture site.

Mean total active motion (TAM) increased significantly from 6 weeks to 3 months and 6 months following surgery, from 193.1 to 207.2 and 214.6 respectively ($p=0.008$). Six months after surgery, TAM was significantly higher than it had been six weeks after surgery ($p0.001$). Healing of the fracture, increased joint mobility, and full function of the finger are all shown by the rise in TAM. Tension band wiring using Kirschner wires provides stability, allowing for early mobility and rehabilitation, which is likely responsible for the improvement. It's worth noting, however, that the pace and amount of functional recovery may be influenced by variables unique to the patient as well as the features of the fracture [14].

In addition, towards the conclusion of the follow-up period, no patient had complained of discomfort while doing routine workplace tasks. This shows that the patient has been effectively treated for pain and is making functional progress after surgery. Nineteen out of twenty patients (95 percent) showed no abnormality during final assessment, indicating that the treatment was successful. One patient, or 5%, had a little dorsal angulation of 10 degrees. These results show that the tension band wiring method is efficient in restoring anatomical alignment and reducing the severity of postoperative abnormalities.

These findings are supported by comparisons to prior research. Similar gains in functional scores and minor abnormalities were also found at the conclusion of the follow-up period in a study evaluating the results of tension band wiring for metacarpal fractures by Wong et al. [15]. Similar positive functional results and minimal rates of

deformity were seen in a study of phalangeal fractures conducted by Lögters et al. [16].

Statistically significantly more improvement in mean hand grip was shown at 3 months post-operation compared to 6 weeks post-operation ($p0.001$). Six months after surgery, there was a statistically significant improvement in hand grip compared to six weeks after surgery ($p0.001$).

Consistent with other research that has measured hand grip strength after surgical procedures for hand fractures, these results are promising. For instance, Dreyfuss et al. [17] found that, regardless of how long it took for the hand's grip strength to fully recover after a tension band wiring procedure for metacarpal fractures, it always increased significantly. Tension band wiring has also been shown to significantly enhance hand grip strength, according to a research concentrating on phalangeal fractures by Lögters et al. [16].

Radiological follow-up revealed that 17/25 patients (86%, mean SD, 8.7 0.8 weeks) had radiological union in under 10 weeks. After 10 weeks, radiological union was established in 3 patients (15 percent), with a mean standard deviation of 11.3.0.6 weeks. Intriguingly, Al Shahat et al. found that radiological union might be identified as early as 6-10 weeks. Eight patients in group A (Kirschner wire) had radiological union at 6 weeks, whereas only seven patients and six patients in the other groups had union at that time [4].

Concluding Remarks

When treating metacarpal and phalangeal fractures, open reduction and internal fixation with Kirschner wires (K-wires) utilising the tension band wiring approach has been shown to be a safe and successful treatment option. Improved range of motion, grip strength, and radiological union are just some of the positive functional results that may be expected from using this method to stabilise a fracture. Most people were able to go back to work quickly, and satisfaction among patients was high.

References

- [1] K.M. Kollitz, W.C. Hammert, N.B. Vedder, J.I. Huang. Metacarpal fractures: treatment and complications. *Hand (N Y)*;9:16-23. 2014
- [2] Z. Ahmed, M.I. Haider, M.I. Buzdar, B. Bakht Chughtai, M. Rashid, N. Hussain, et al. Comparison of Miniplate and K-wire in the Treatment of Metacarpal and

- Phalangeal Fractures. *Cureus*;12:e7039. 2020
- [3] m.m. Abdel-hamid, M.I. Abulsoud, M.m. bissar. Comparative Study Between Intramedullary K Wires Versus Mini-plates and Screws in Fixation of Metacarpal Shaft Fractures in Adults. *AIMJ*;1:299-305. 2020
- [4] O.A. Al Shahat, Y.H. Ismail, M.H. Al Kaseer, A.S. El Genidy. Management of Metacarpal and Phalangeal Bone Fractures of the Hand. *The Egyptian Journal of Plastic and Reconstructive Surgery*;42:405-9. 2018
- [5] F.A. Alhumaid, S.T. Alturki, S.H. Alshareef, O.S. Alobaidan, A.A. Alhuwaymil, N.S. Alohaideb, et al. Epidemiology of hand fractures at a tertiary care setting in Saudi Arabia. *Saudi Med J*;40:732-6. 2019
- [6] C. Bergh, D. Wennergren, M. Möller, H. Brisby. Fracture incidence in adults in relation to age and gender: A study of 27,169 fractures in the Swedish Fracture Register in a well-defined catchment area. *PLoS One*;15:e0244291. 2020
- [7] J.N. Farr, L.J. Melton, 3rd, S.J. Achenbach, E.J. Atkinson, S. Khosla, S. Amin. Fracture Incidence and Characteristics in Young Adults Aged 18 to 49 Years: A Population-Based Study. *J Bone Miner Res*;32:2347-54. 2017
- [8] T. Sterud, T. Tynes, I.S. Mehlum, K.B. Veiersted, B. Bergbom, A. Airila, et al. A systematic review of working conditions and occupational health among immigrants in Europe and Canada. *BMC Public Health*;18:770. 2018
- [9] D.S. Bhatti, N.U. Ain, M. Fatima. Occupational Hand-Related Injuries at a Major Tertiary Care Burn and Reconstructive Center in Pakistan. *Cureus*;12:e10444. 2020
- [10] B.H. Miranda, Z.P. Spilsbury, A. Rosala-Hallas, S. Cerovac. Hand trauma: A prospective observational study reporting diagnostic concordance in emergency hand trauma which supports centralised service improvements. *J Plast Reconstr Aesthet Surg*;69:1397-402. 2016
- [11] R.H. van Leerdam, P. Krijnen, M.J. Panneman, I.B. Schipper. Incidence and treatment of hand and wrist injuries in Dutch emergency departments. *European Journal of Trauma and Emergency Surgery*;48:4327-32. 2022
- [12] D. Haughton, D. Jordan, M. Malahias, S. Hindocha, W. Khan. Principles of hand fracture management. *Open Orthop J*;6:43-53. 2012
- [13] C. Meals, R. Meals. Hand fractures: a review of current treatment strategies. *J Hand Surg Am*;38:1021-31; quiz 31. 2013
- [14] S.C. van der Linden, A. van Kampen, R.L. Jaarsma. K-wire position in tension-band wiring technique affects stability of wires and long-term outcome in surgical treatment of olecranon fractures. *J Shoulder Elbow Surg*;21:405-11. 2012
- [15] K.P. Wong, R.A. Hay, S.C. Tay. Surgical outcomes of fifth metacarpal neck fractures--a comparative analysis of dorsal plating versus tension band wiring. *Hand Surg*;20:99-105. 2015
- [16] T.T. Lögters, H.H. Lee, S. Gehrman, J. Windolf, R.A. Kaufmann. Proximal Phalanx Fracture Management. *Hand (N Y)*;13:376-83. 2018
- [17] D. Dreyfuss, R. Allon, N. Izacson, D. Hutt. A Comparison of Locking Plates and Intramedullary Pinning for Fixation of Metacarpal Shaft Fractures. *Hand (N Y)*;14:27-33. 2019